

**Chang Gung Memorial Hospital**

## Case conference

R3 陳思元  
VS 徐郭堯  
2010.08.19

**KNEE RECONSTRUCTION & SPORTS MEDICINE**



## 75-year-old woman


Chief complaint  
– Progressive left anterior knee pain

Housewife  
159cm 64kg  
No systemic diseases or chronic medication  
No tobacco & alcohol use  
10515467 倪○陳麗玉


**KNEE RECONSTRUCTION & SPORTS MEDICINE**



Left knee stand-up weakness and pain after long-term sitting  
Symptoms for 9 years, aggravated in recent one year  
No fever, or resting/ night pain



**KNEE RECONSTRUCTION & SPORTS MEDICINE**




Physical examination:

- PF joint tenderness over lateral facet
- No patellar obvious translation or dislocation
- No varus or valgus malalignment, full knee range of motion

Laboratory data:

- WBC=4900/uL, Hb=12g/dL, PLT=180K/dL, ESR=23mm/hr, CRP=0.96

**KNEE RECONSTRUCTION & SPORTS MEDICINE**



## 2010.06.15 left knee



Asymmetric joint space narrowing

**KNEE RECONSTRUCTION & SPORTS MEDICINE**



## Conservative treatment

- Weight loss
- Lifestyle & daily activity modification
- Quadriceps strengthening exercises
- Anti-inflammatory agents




**KNEE RECONSTRUCTION & SPORTS MEDICINE**



## Surgical intervention

- Lateral release
- Patellar realignment
  - Fulkerson (distalization & medialization)
  - Maquet (anteriorization)





R3 陳思元

KNEE RECONSTRUCTION & SPORTS MEDICINE

## Surgical intervention

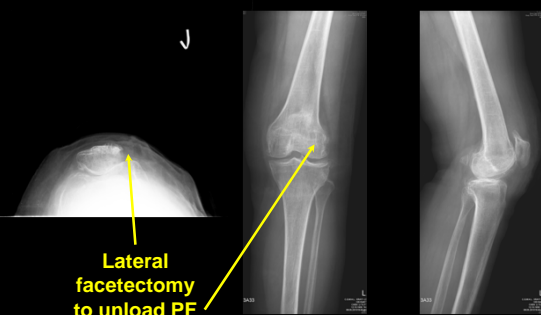
- Trochleoplasty for TD
- Patellectomy
- Patellofemoral joint replacement
- Total knee arthroplasty



R3 陳思元

KNEE RECONSTRUCTION & SPORTS MEDICINE

## 2010.08.04 operation



Lateral facetectomy to unload PF joint

R3 陳思元

長庚紀念醫院  
Chang Gung Memorial Hospital



TAIWAN

R3 陳思元

KNEE RECONSTRUCTION & SPORTS MEDICINE